

Top 10 differential diagnoses in family medicine: Low back pain

David Ponka MD Michael Kirlaw MD

3. LOW BACK PAIN

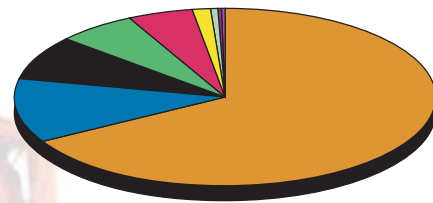
Despite the frequency of this complaint, a specific anatomic diagnosis is often elusive, and can be counter-productive, as different practitioners invariably disagree on specific anatomical diagnoses, thus confusing the patient.

Useful, common categorization, affecting approach to treatment and follow-up, is as follows:

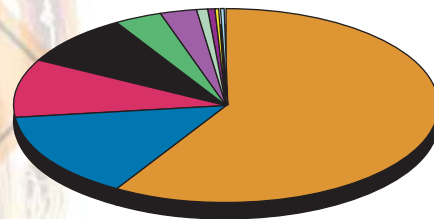
- Ddx

 - acute mechanical low-back pain/strain;
 - sciatica/radiculopathy;
 - DDD;
 - inflammatory causes include the spondyloarthropathies, characterized by significant stiffness and limited range of motion;
 - leading to intermittent claudication that is worse when walking perfectly upright;
 - rare serious causes include neoplasm (usually metastases), infections (discitis, TB) and cauda equina syndrome; and
 - also consider visceral causes, including pelvic infections, nephrolithiasis, pancreatic disease and AAA.

In the absence of red flags, xrays can be counter-productive, but are reasonable in the context of trauma, the elderly, or known osteoporosis.



Under 45



45 and Older

	AGE	
	Under 45	45 and Older
Mechanical Low Back Pain	67.10 %	58.70 %
Sciatica	8.00	8.50
Muscle Strain	6.30	3.80
DDD	4.80	9.60
Osteoporosis	0.07	2.80
RA	0.40	0.50
UTI	0.50	0.80
Nephrolithiasis	1.20	0.40
Prostate CA	0.00	0.30
Other	11.60	14.60

AAA—abdominal aortic aneurysm; CA—cancer; DDD—degenerative disc disease; RA—rheumatoid arthritis; TB—tuberculosis; UTI—urinary tract infection.

For a pdf of the Top Ten Differential Diagnoses in Family Medicine pamphlet or to access the slide show on-line, go to <http://www.familymedicine.uottawa.ca/eng/TopTenDifferentialDiagnosisInPrimaryCare.aspx>.

Dr Ponka is an Assistant Professor and Dr Kirlaw is a second-year resident in the Department of Family Medicine at the University of Ottawa in Ontario.

Correspondence to: Dr David Ponka, Assistant Professor, Department of Family Medicine, University of Ottawa; e-mail dponka@uottawa.ca